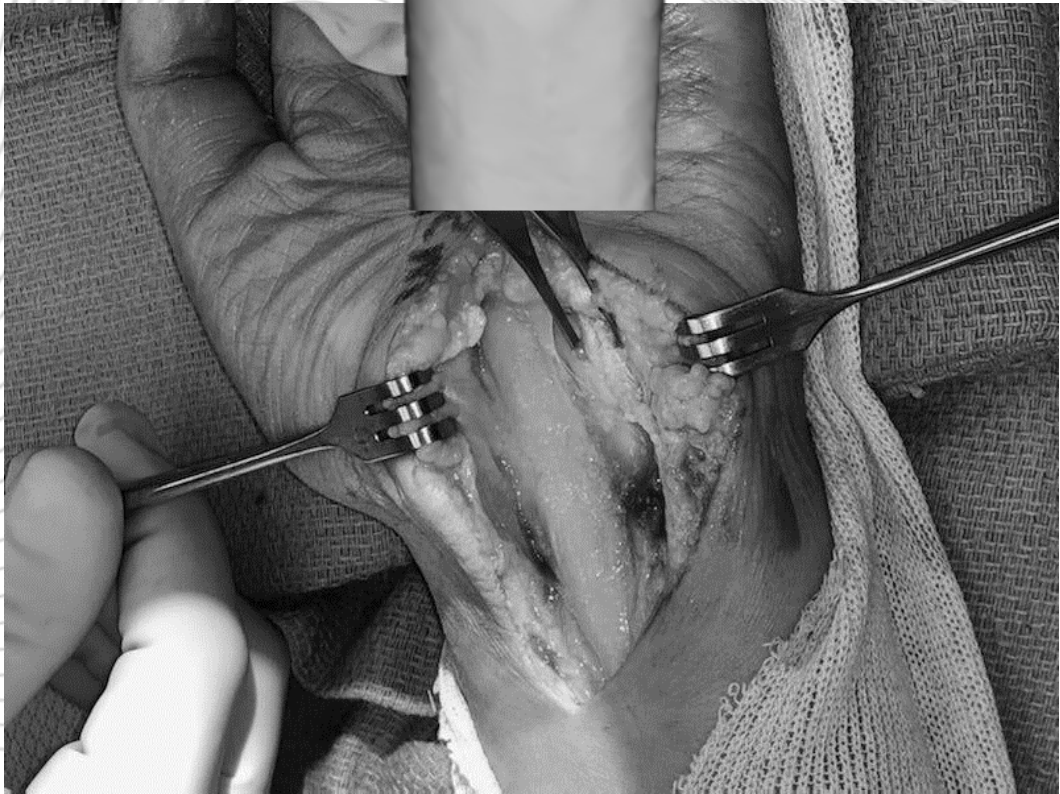
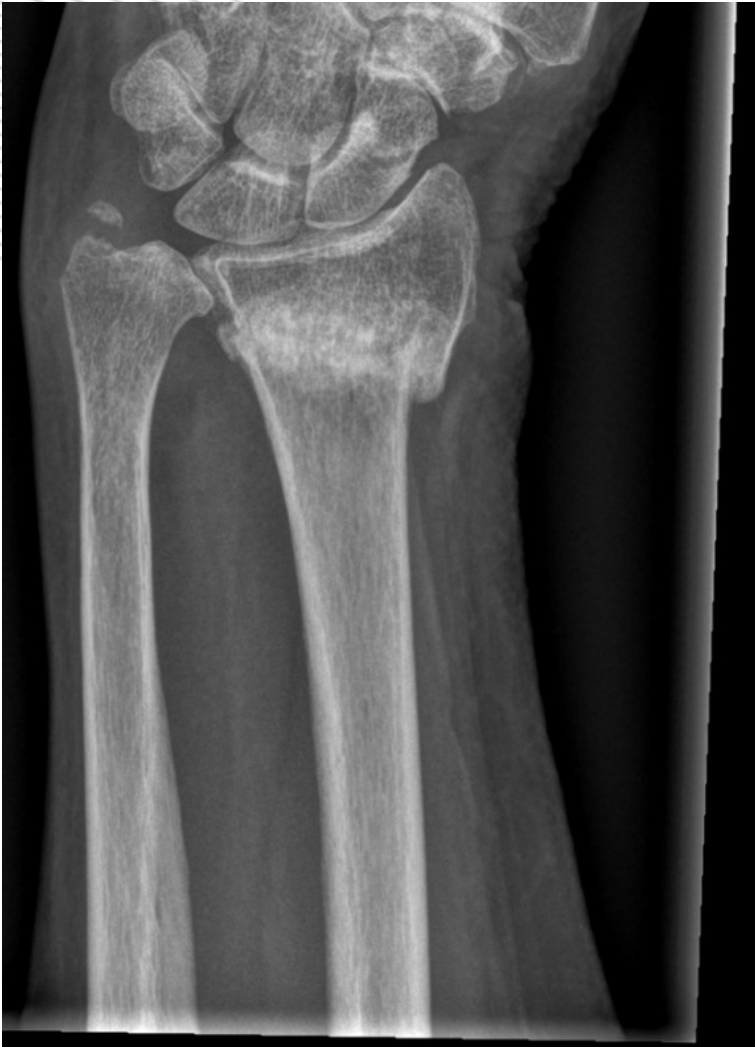

A COMPARISON OF 3D CT AND 2D PLAIN RADIOGRAPH MEASUREMENTS OF THE WRIST IN EXTRA-ARTICULAR MALUNITED FRACTURES OF THE DISTAL RADIUS

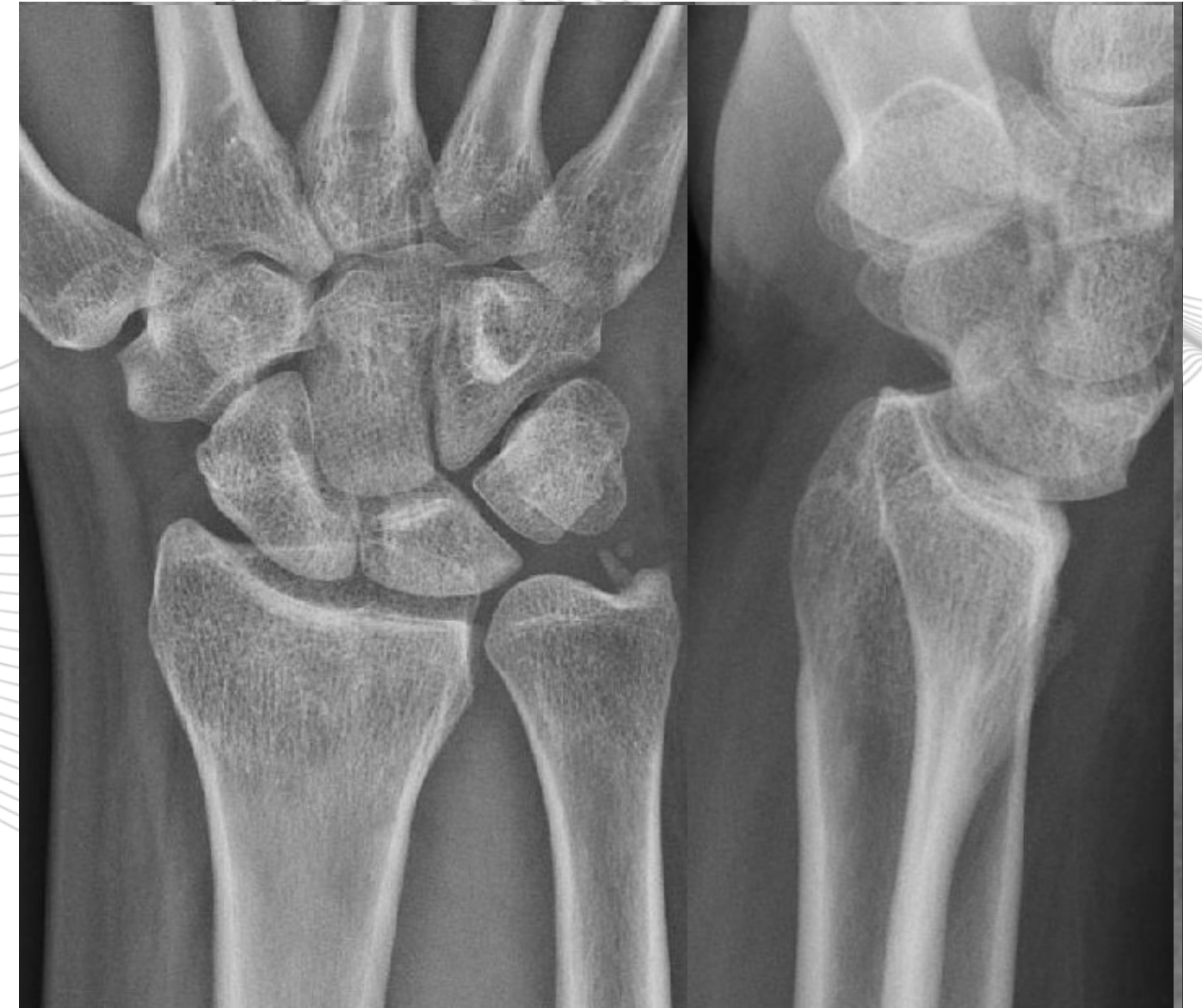CAMIEL SMEES, MSc - OCON / ET BDDP

IMAGINE



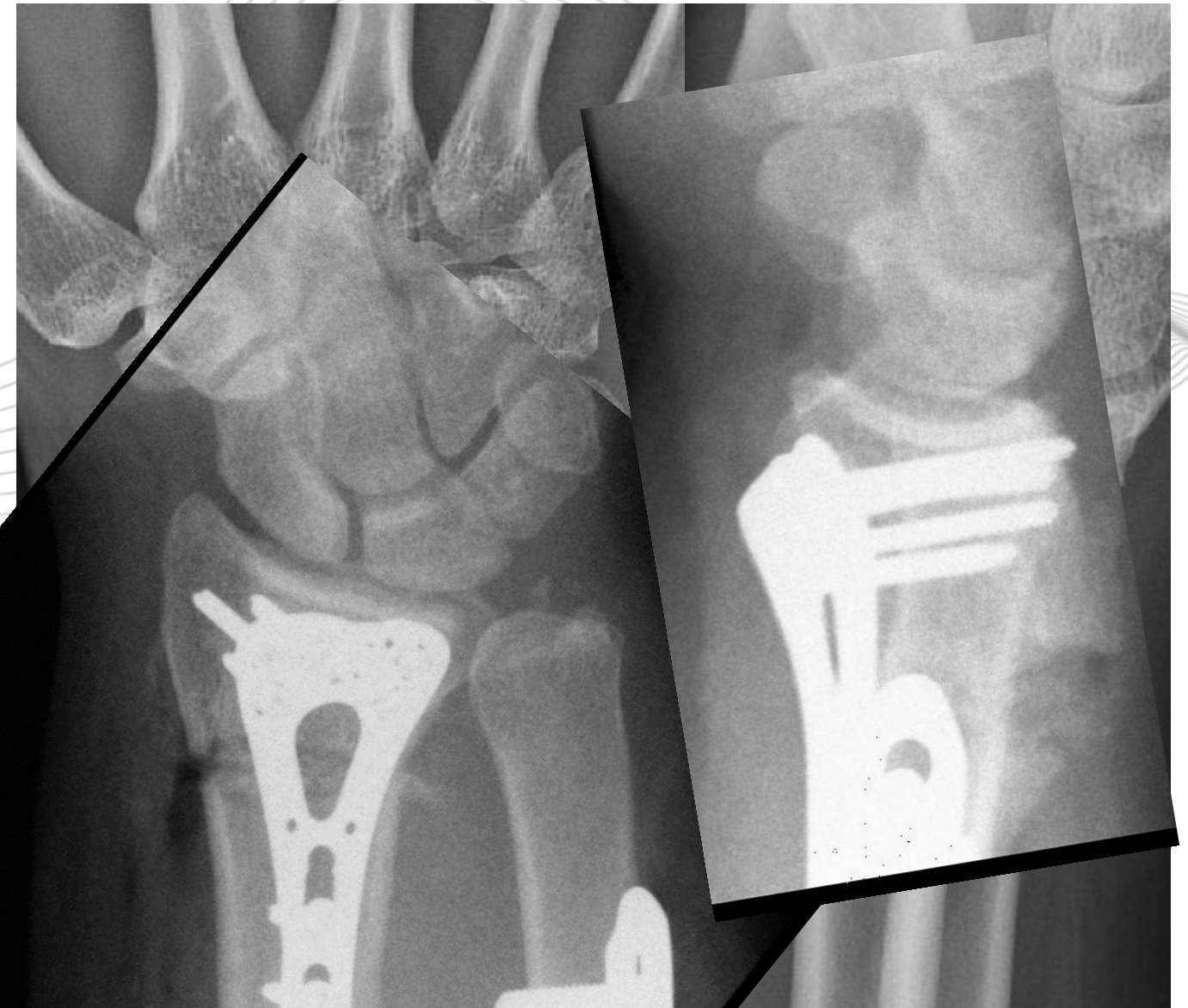
DISTAL RADIUS FRACTURE

- ~25/10.000 person year
- Treatment
 - Cast
 - Surgical intervention
- Malunion 17-33%

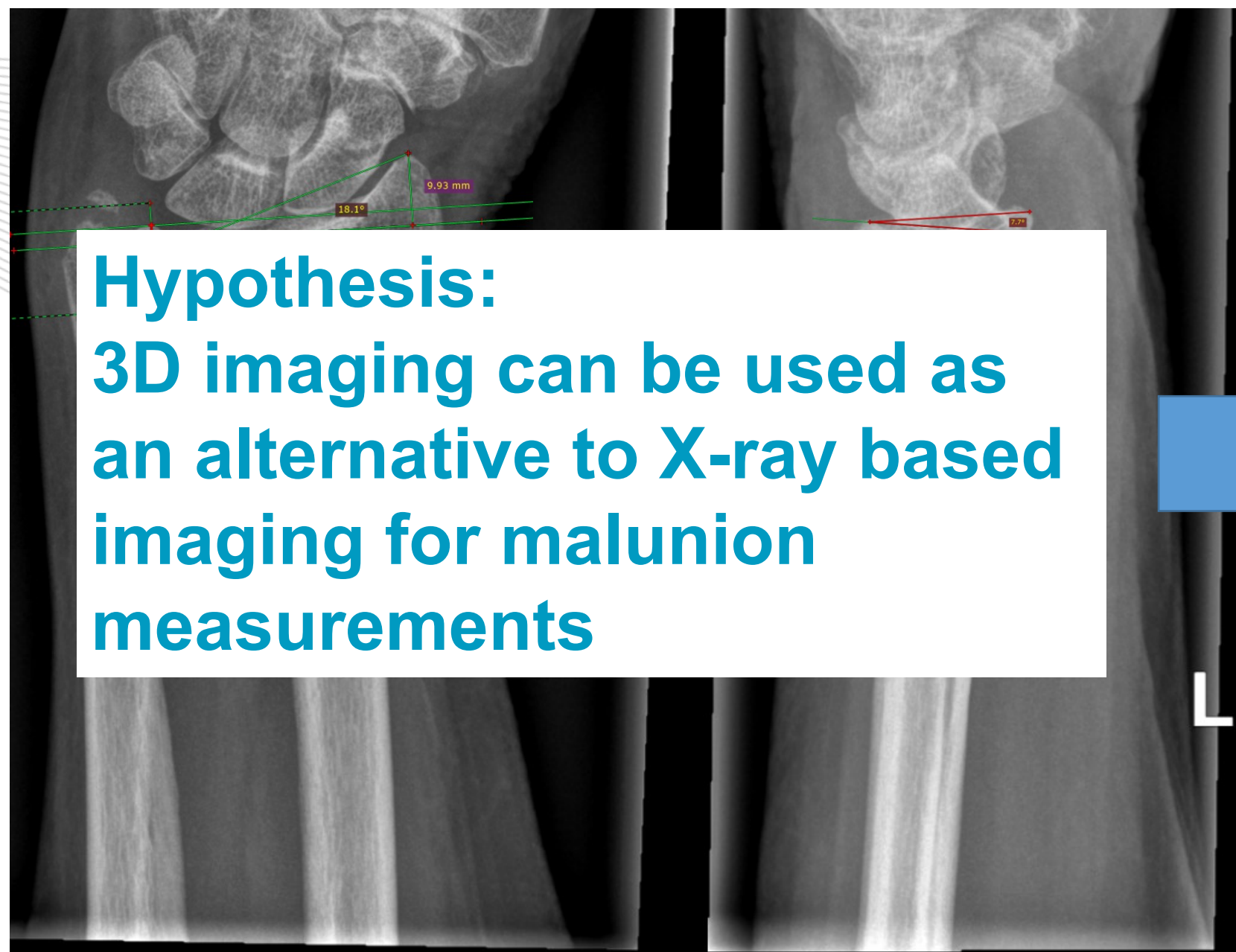


DISTAL RADIUS MALUNION

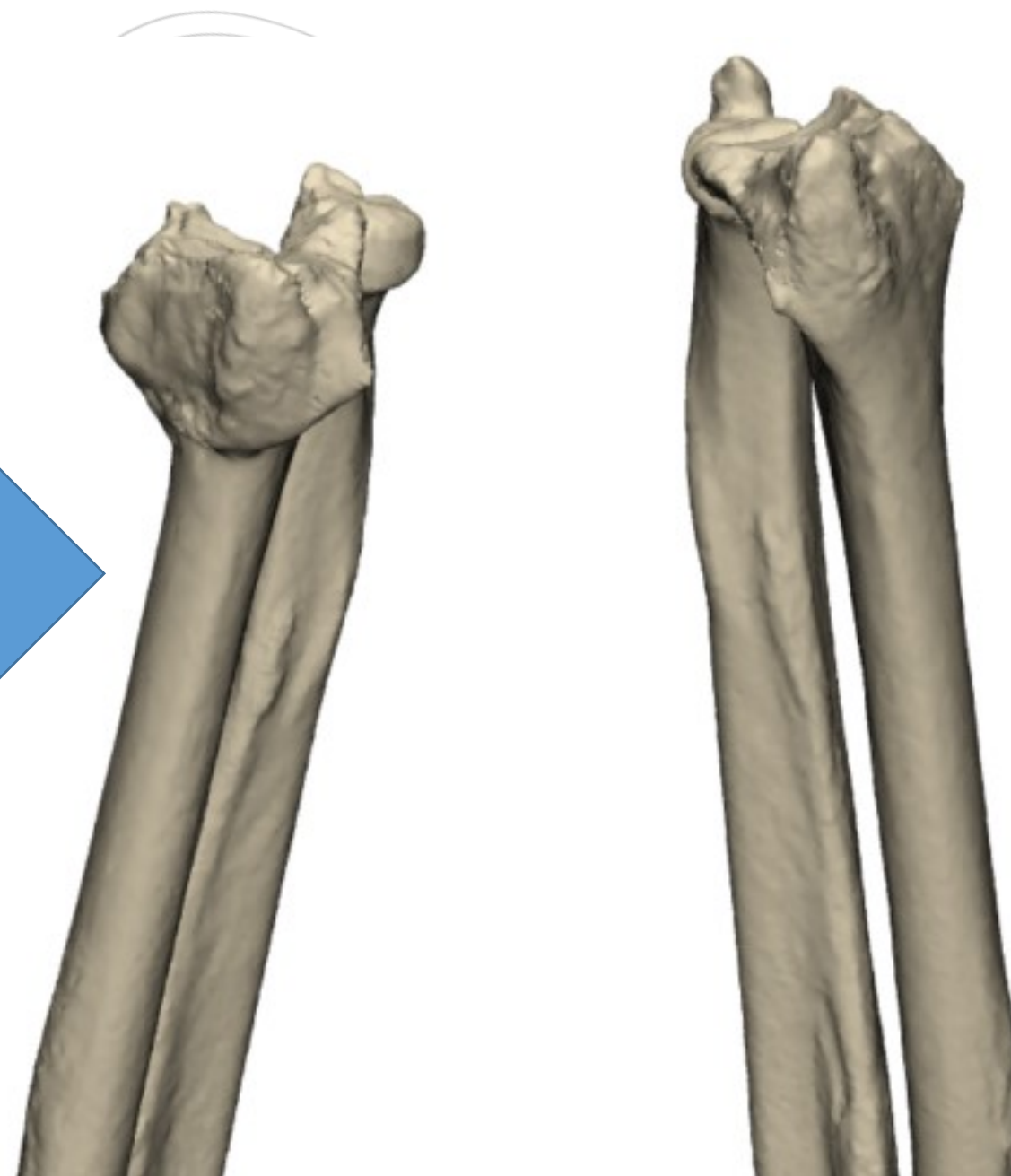
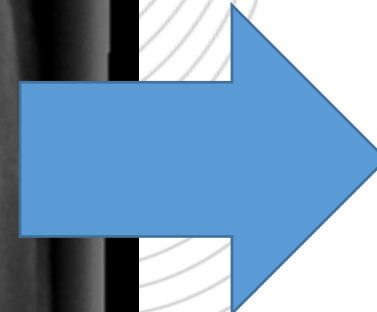
- **Diagnosis**
 - X-ray
 - Function
 - Questionnaires
- **Surgical treatment**
 - Conventional
 - X-ray Images
 - 3D Surgical guides
 - CT-scan




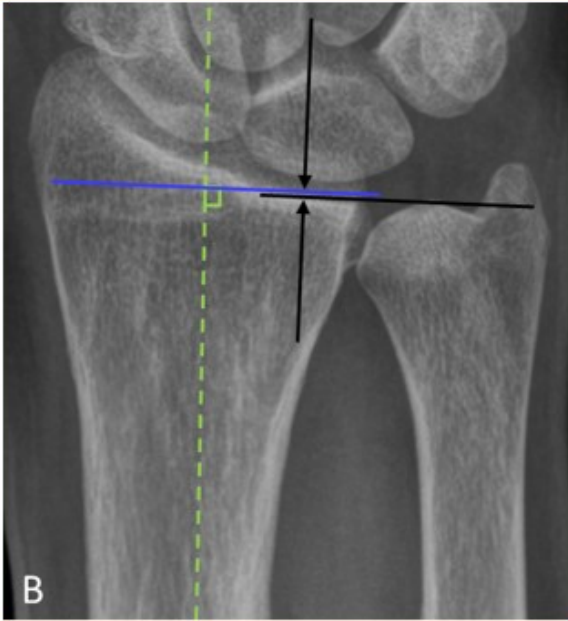

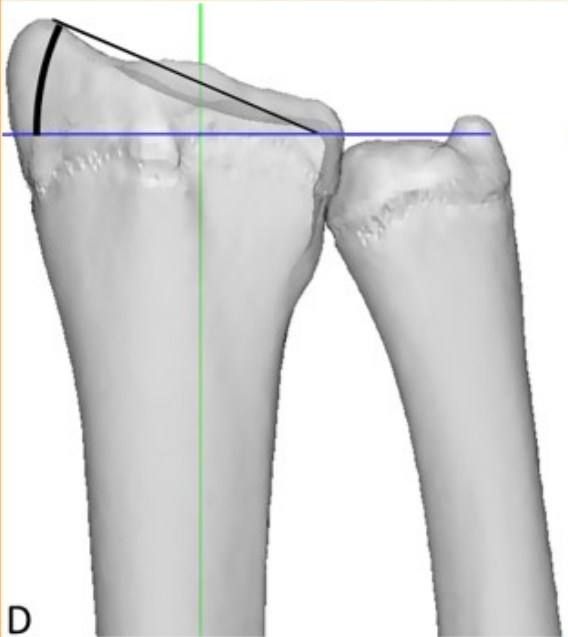
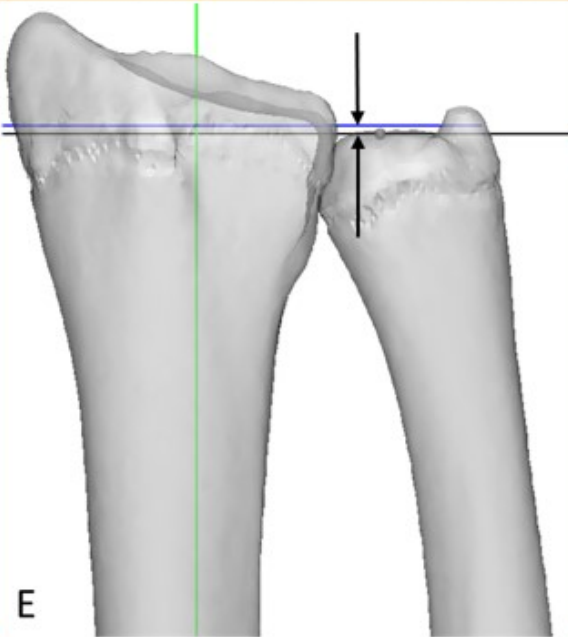
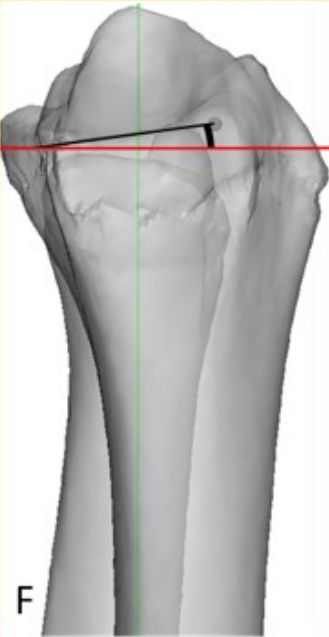
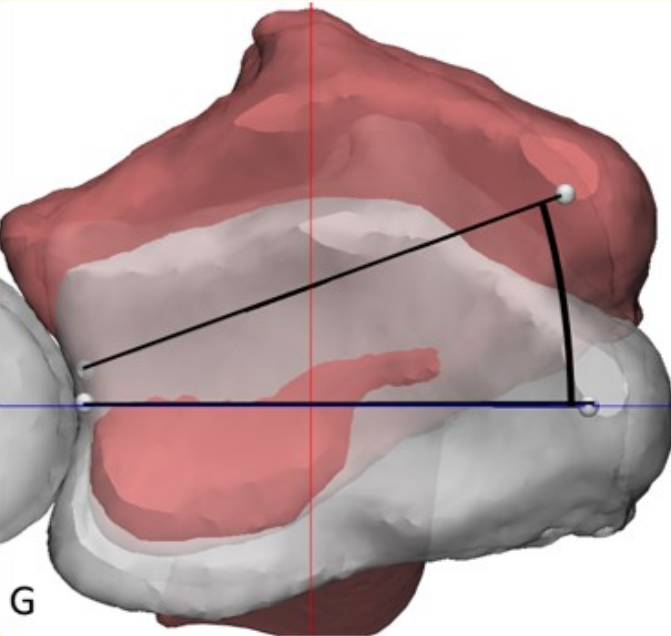
RATIONALE



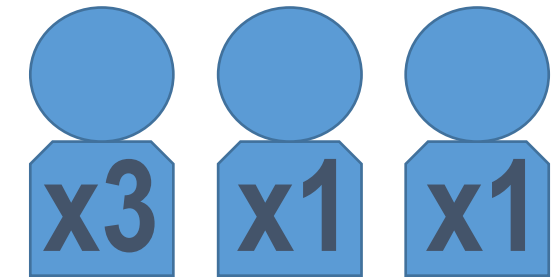
Hypothesis:
3D imaging can be used as
an alternative to X-ray based
imaging for malunion
measurements



METHODS

	Radial Inclination	Ulnar Variance	Palmar Tilt	Axial Rotation
2D	 A	 B	 C	Not possible
3D	 D	 E	 F	 G

Observers

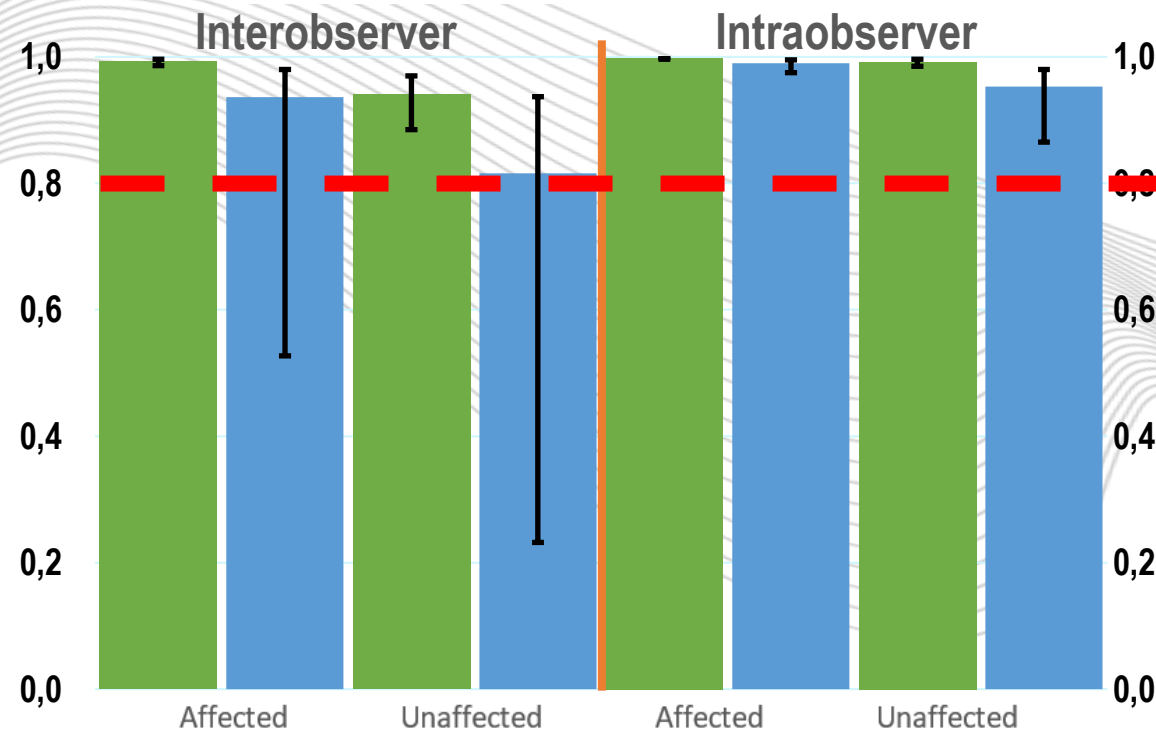


RESULTS

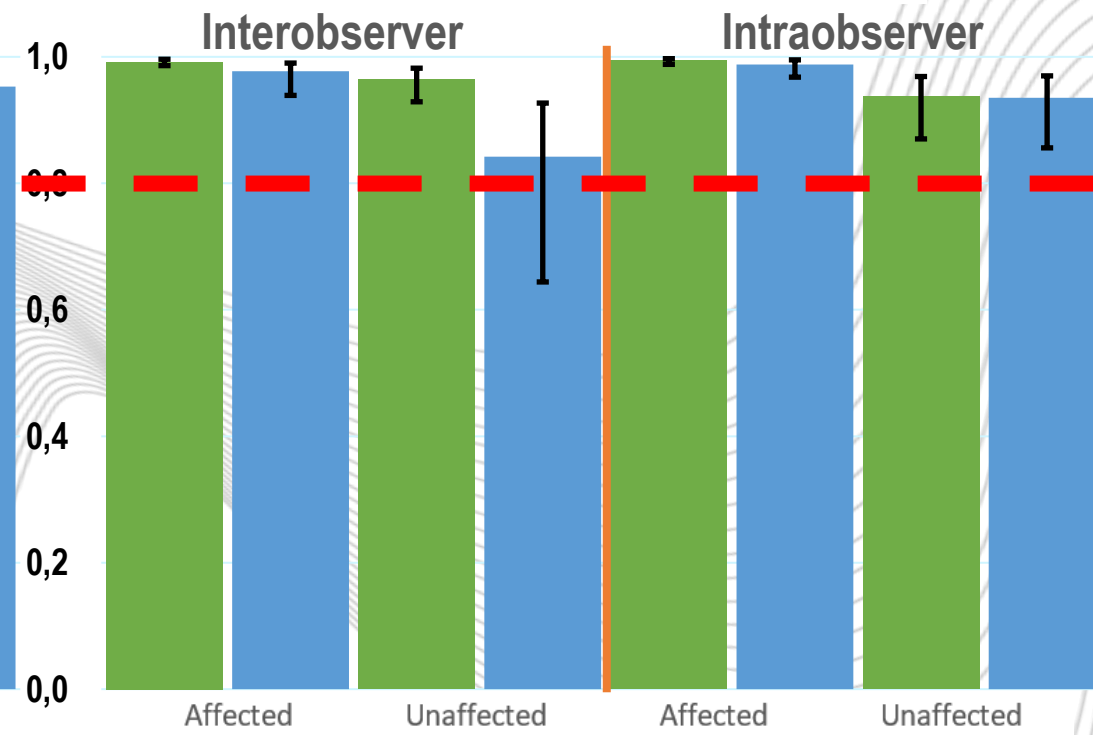
ICC

■ 3D ■ 2D

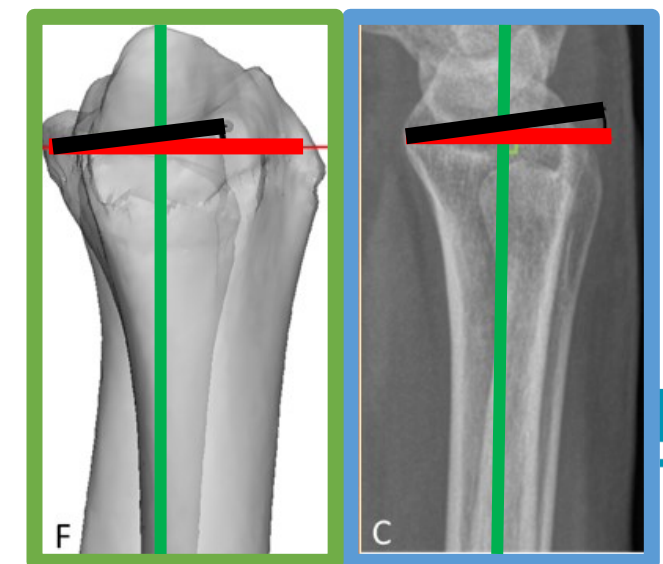
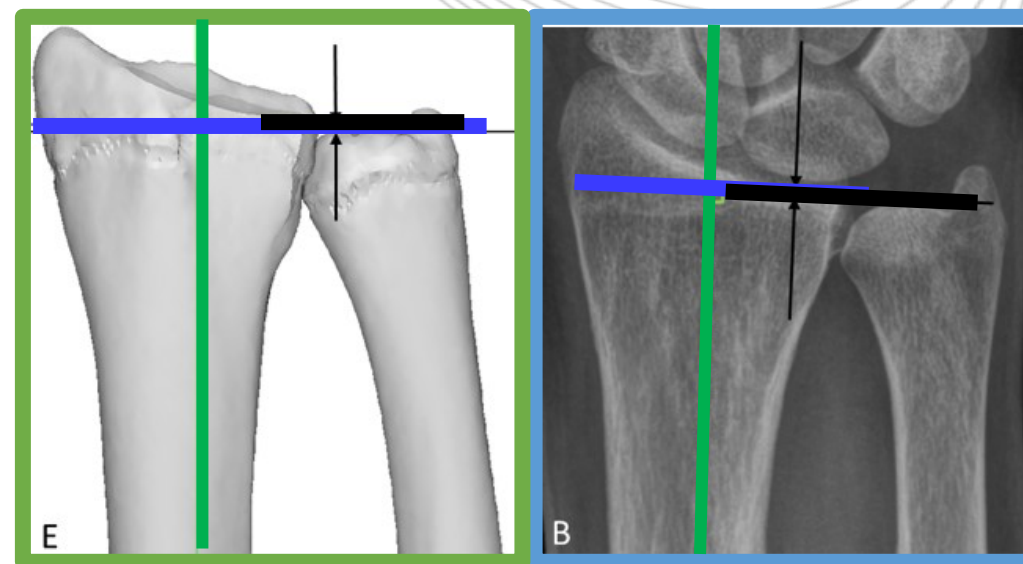
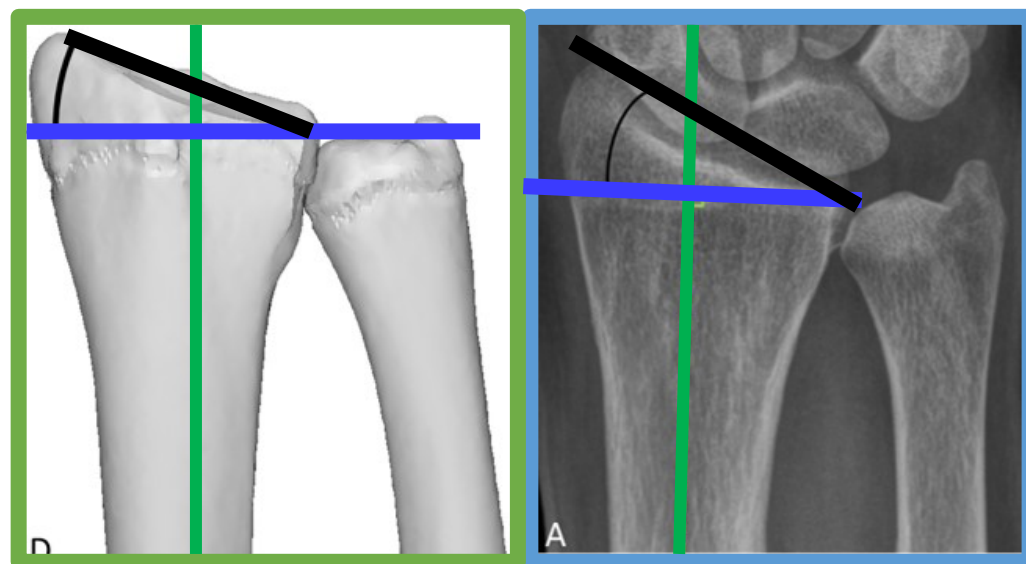
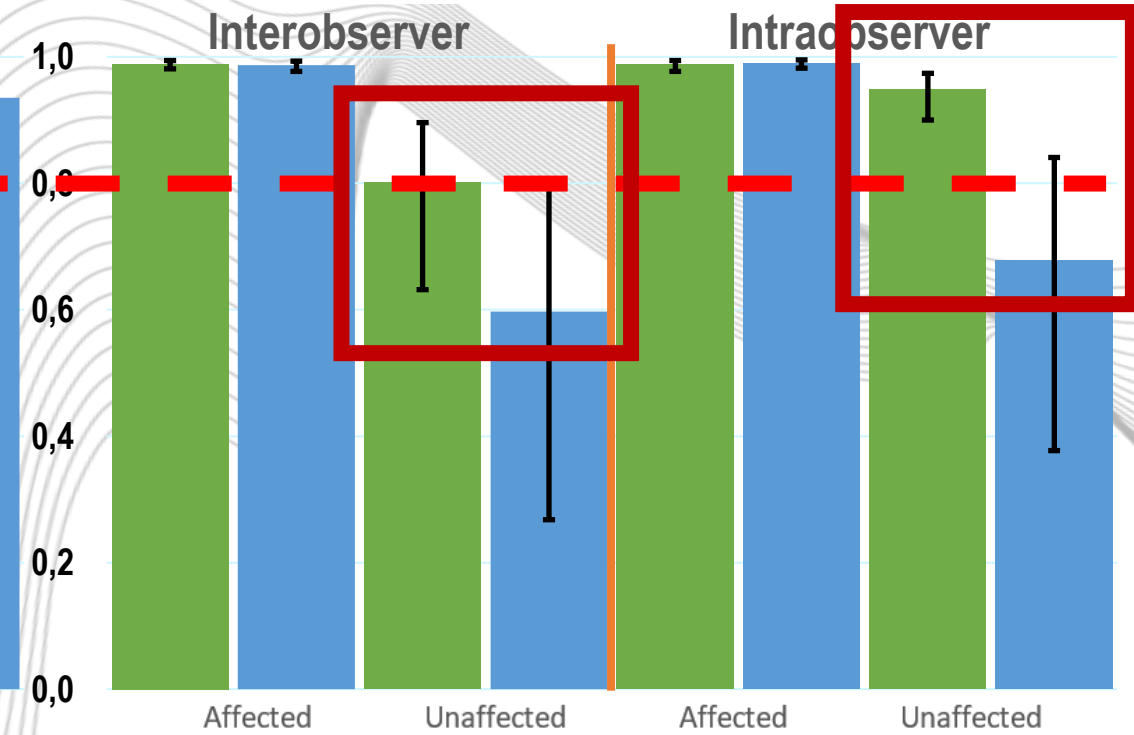
Radial Inclination



Ulnar Variance



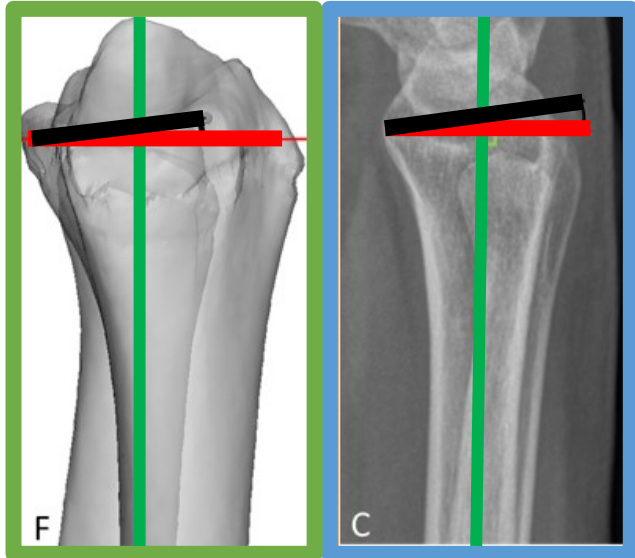
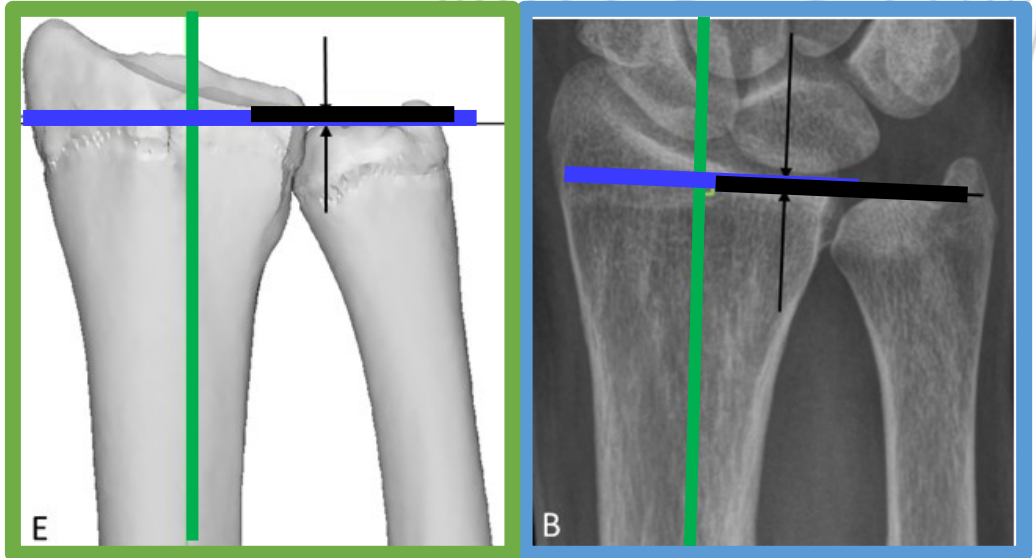
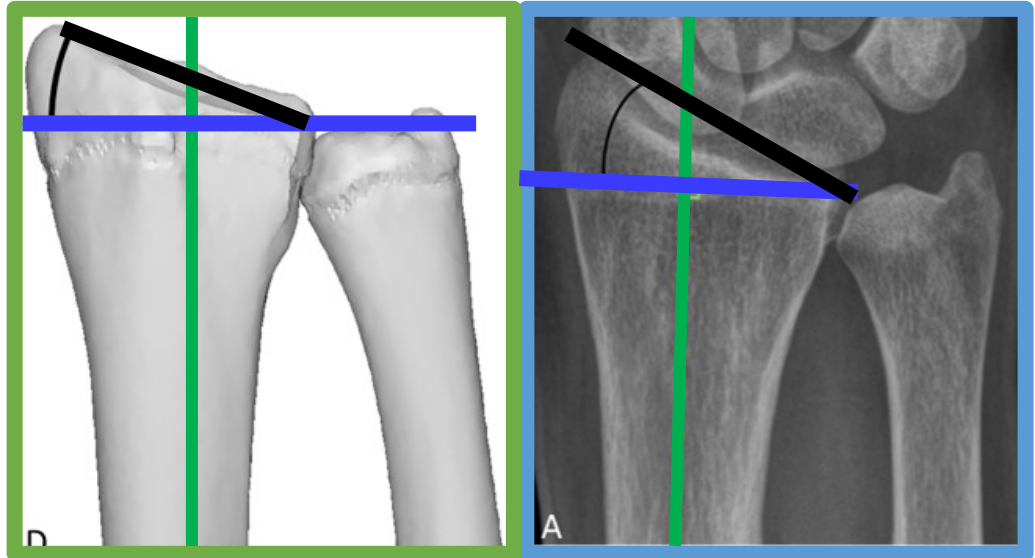
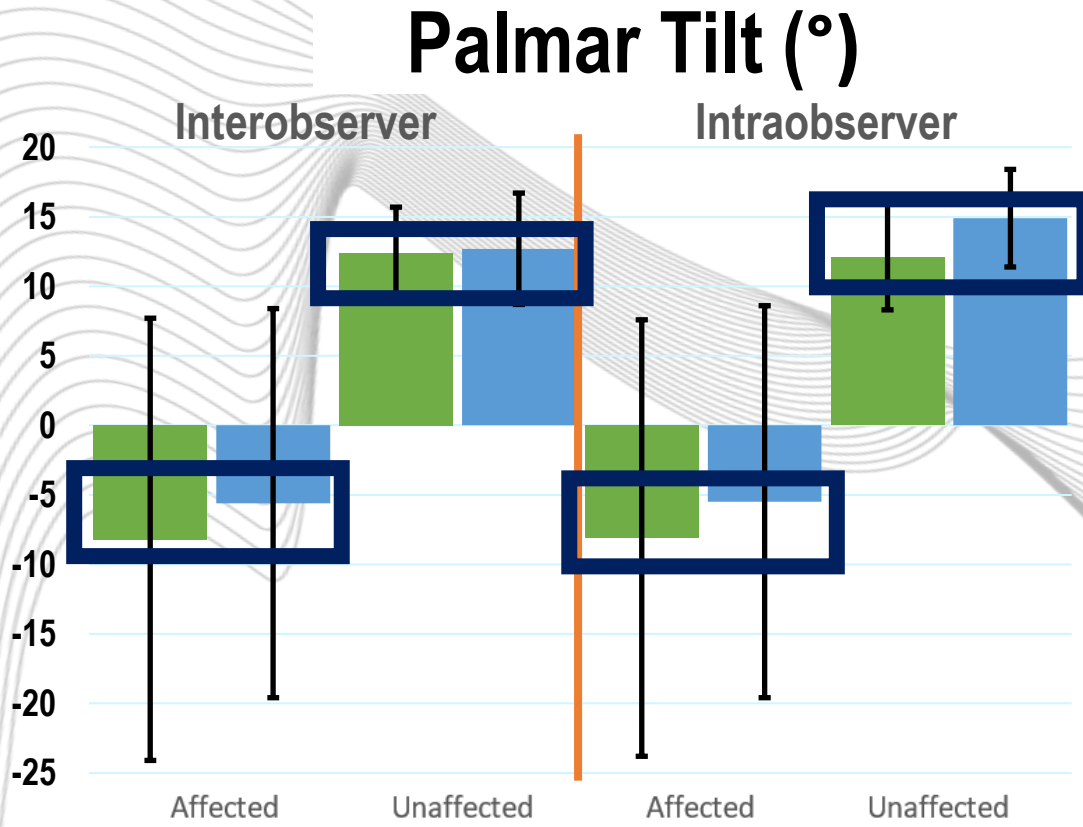
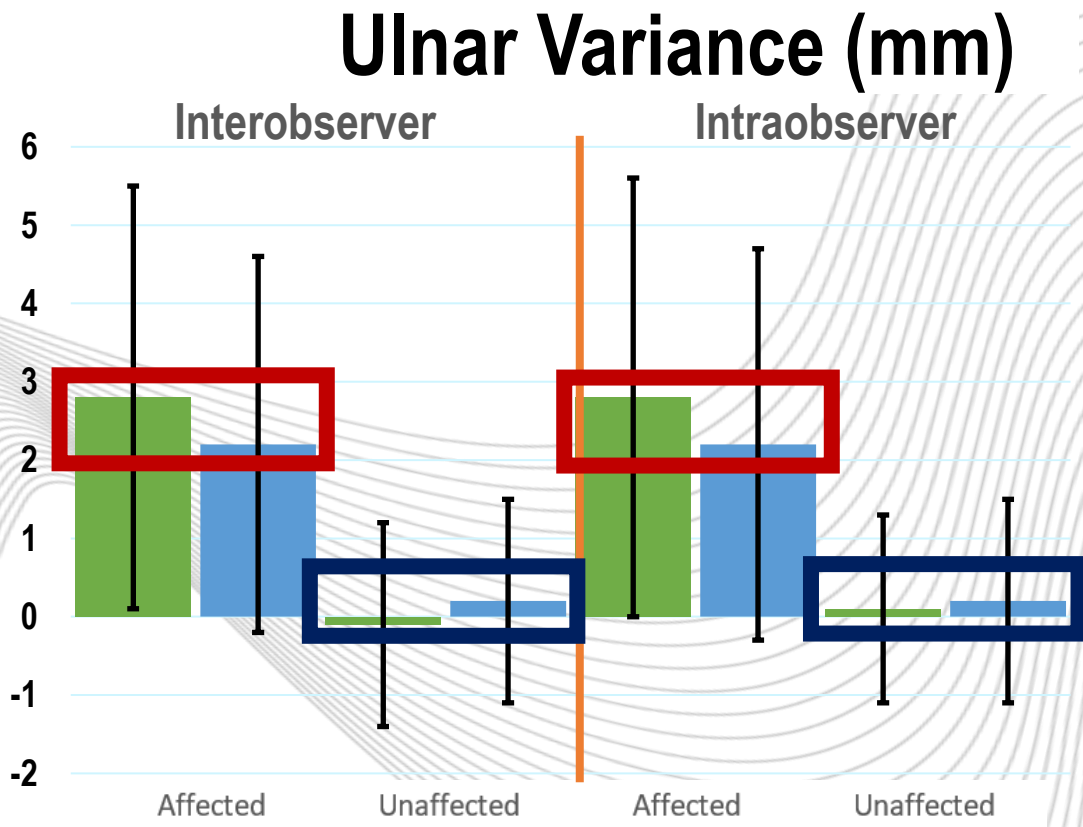
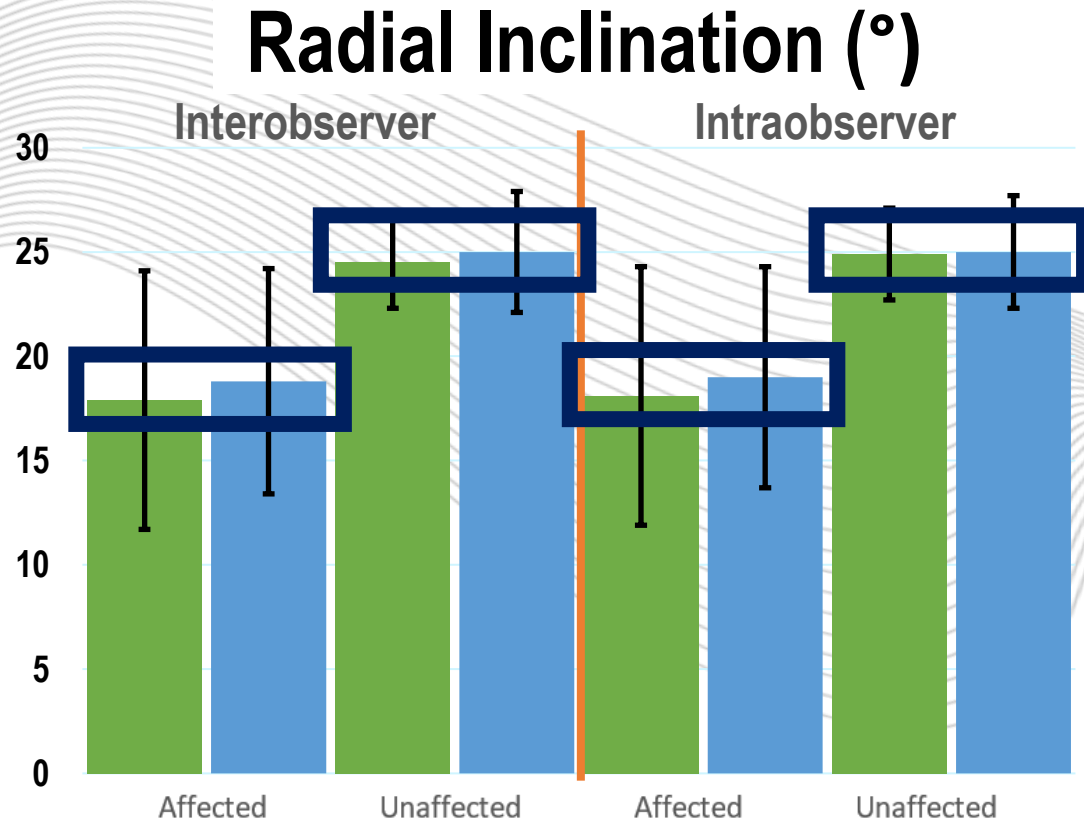
Palmar Tilt



RESULTS

ABSOLUTE

■ 3D ■ 2D



CONCLUSION

In this study we:

- **Developed standardised 3D measuring protocol**
- **Found that reliability of 3D measurements is higher than 2D measurements**
- **Found normal values for malunion in 3D**

THE TEAM



ocean
Orthopedische kliniek



BDDP | Biomedical Device
Design & Production

COLLABORATE?

C.J.SMEES@UTWENTE.NL

