



Pioneering Perspectives: Sensing and Imaging as Key Enabling Technologies

Srirang Manohar, University of Twente

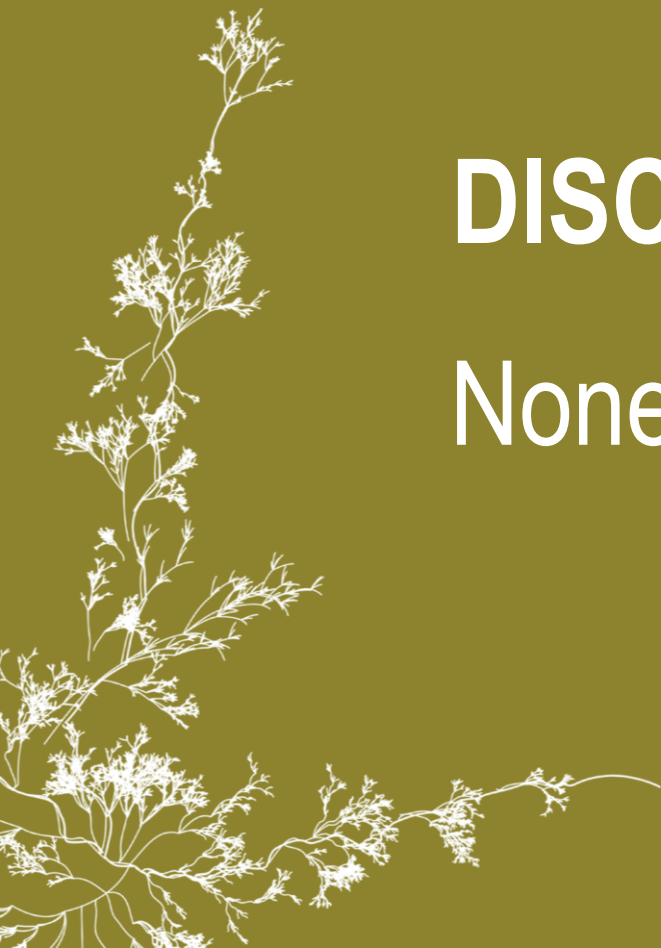Advancing Photoacoustic Technologies for Medical Applications

Srirang Manohar, Prof. Dr.
Multi-Modality Medical Imaging
TechMed Centre
University of Twente



DISCLOSURES

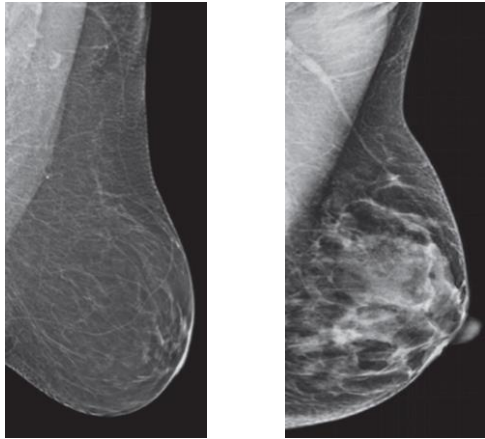
None



IMAGING IN BREAST CANCER

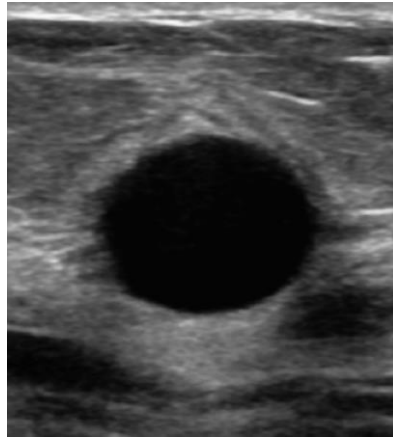
X-ray mammography

- Painful compression
- Ionizing radiation
- Poor performance dense breast



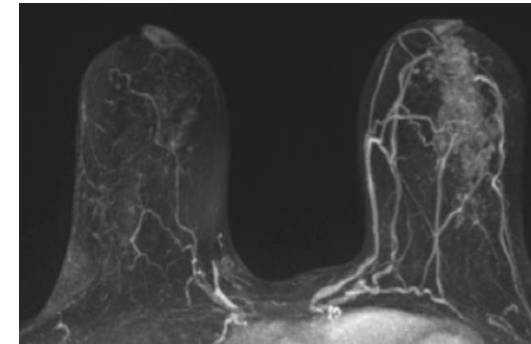
Ultrasonography

- High false positive rate
- Limited FOV of breast
- Operator dependent

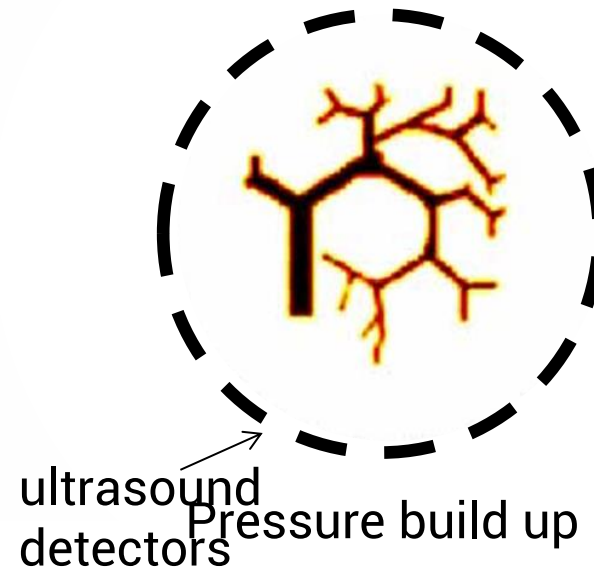


Magnetic resonance imaging

- Contrast agent
- Expensive & low availability
- Poor specificity

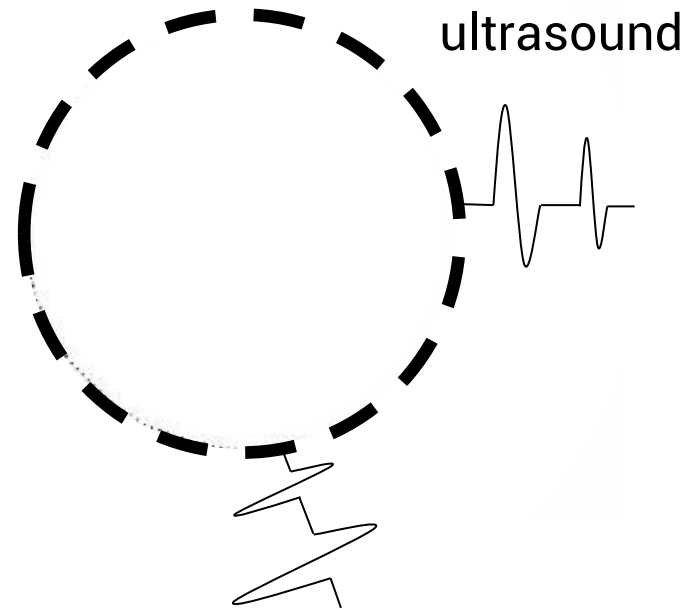


PRINCIPLE OF PHOTOACOUSTICS




- ➡ Absorption of light
- ➡ Temperature rise
- ➡ Thermal expansion

PRINCIPLE OF PHOTOACOUSTICS



PRINCIPLE OF PHOTOACOUSTICS

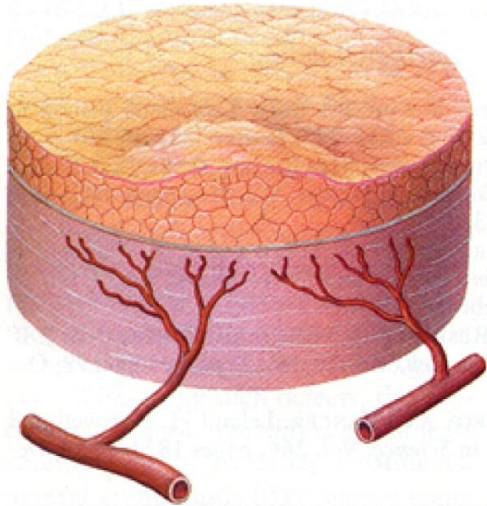
TIME REVERSAL



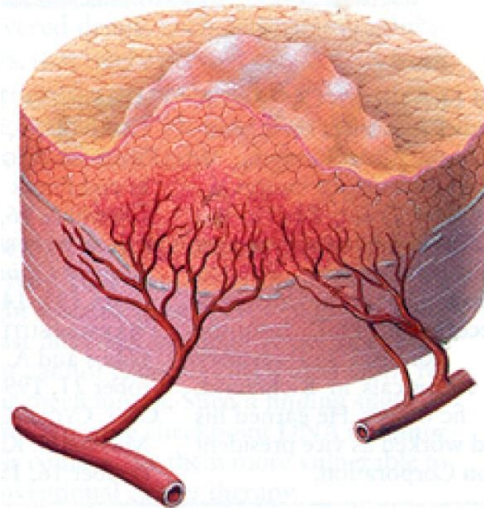
CANCER AND ANGIOGENESIS

Angiogenesis and progression of a tumor

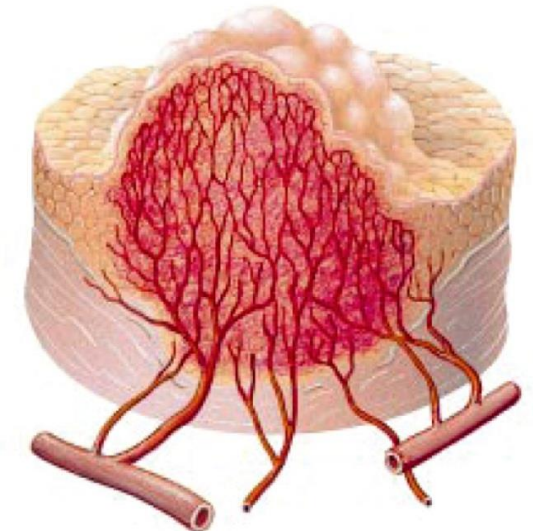
In-situ tumor



Capillaries proliferate;
tumor begins to grow



Full-blown cancer



Uni. Of Twente, NL

Maura Dantuma
Rianne Bulthuis
Bruno DeSanti
Esther Bosman
Johan van Hespem
Saskia Kruitwagen
Sjoukje Schoustra
David Thompson
Tom Knop
Wilma Petersen
Lioe-Fee de Geus-Oei

UCL, UK

Felix Lucka (Also CWI, NL)
Ashkan Javaherian
Bradley E. Treeby
Ben T. Cox

PA Imaging R&D, NL

Laurens Alink
Martin Nanninga
Rutger Pompe van Meerdervoort
Tim op t Root
Roeland Huijink
Wouter Muller-Kobold
Paul Nederkoorn

BUT, CZ

Jakub Budisky
Gabriel Bordovsky
Jiri Jaros

Ekspla, LT

Tomas Kasponas
Andrejus Michailovas

Uni. Bern, CH

Martin Frenz
Michael Jaeger

Imasonic, FR

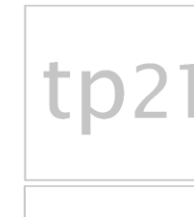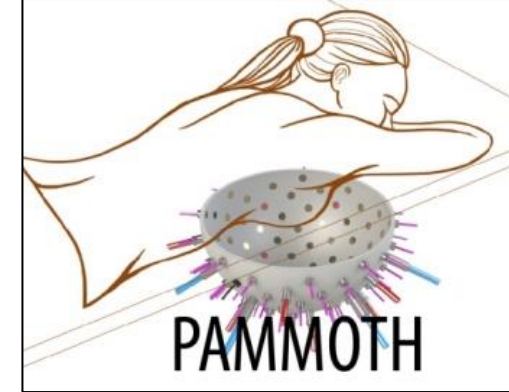
Frédéric Brochin
Theo Martinez

MST & ZGT, NL

Saskia H. Aarnink (MST, NL)
Margreet van der Schaaf (MST, NL)
Carolien Klazen (MST, NL)
Job van der Palen (MST, NL)
Mariel Brinkhuis (Labpon, NL)
Jeroen Veltman (ZGT, NL)
Mart van der Laar (MST, NL)



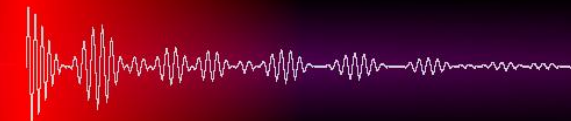H2020-ICT-29-2016
nr. 732411



UNIVERSITY OF TWENTE.



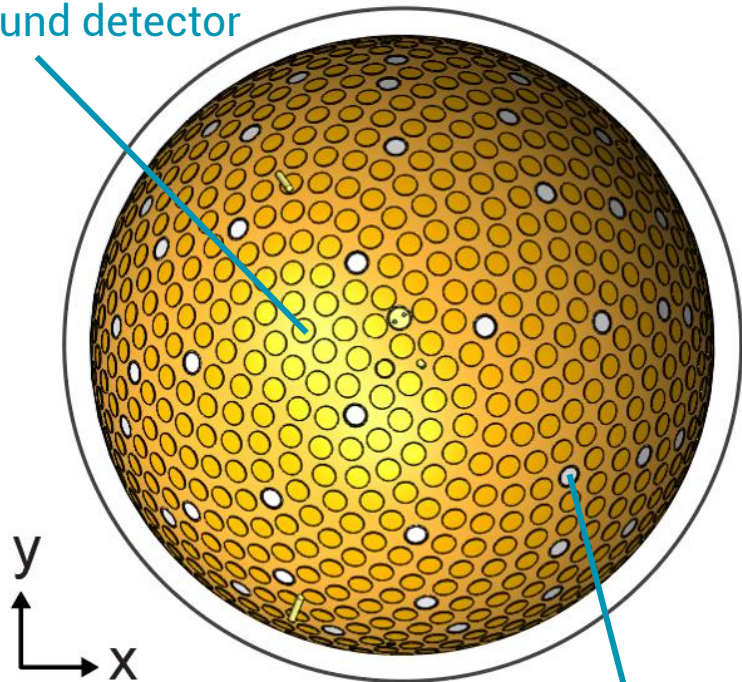
PA Imaging



PAM3 SYSTEM

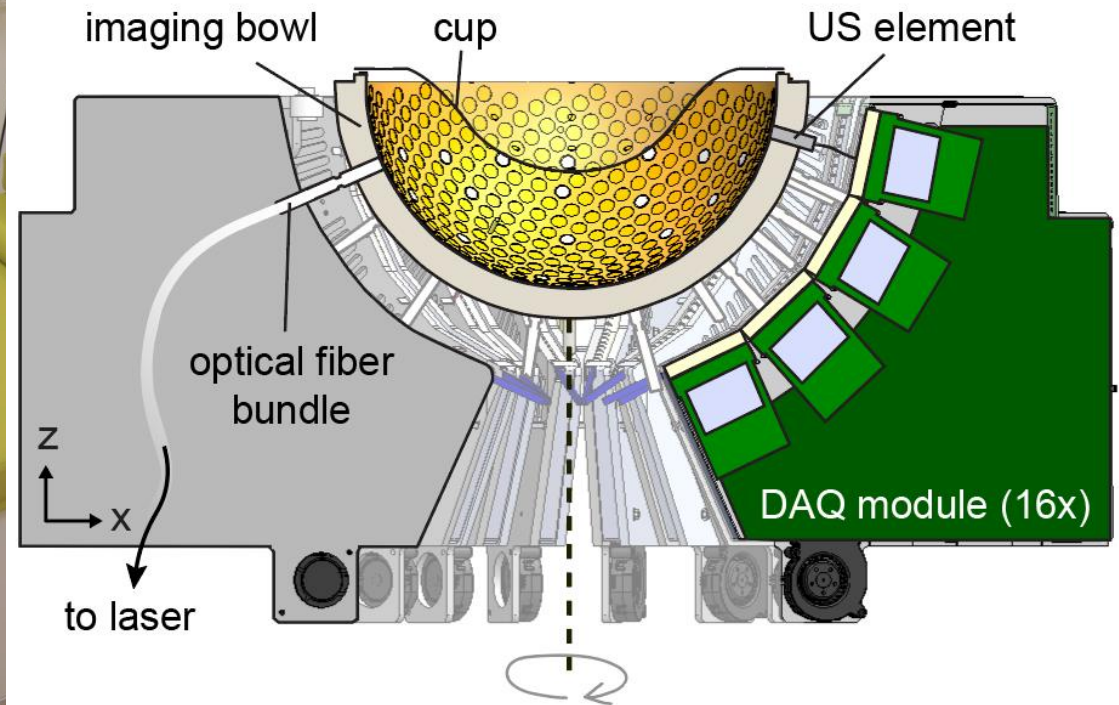
imaging tank – top view

Ultrasound detector
(512x)

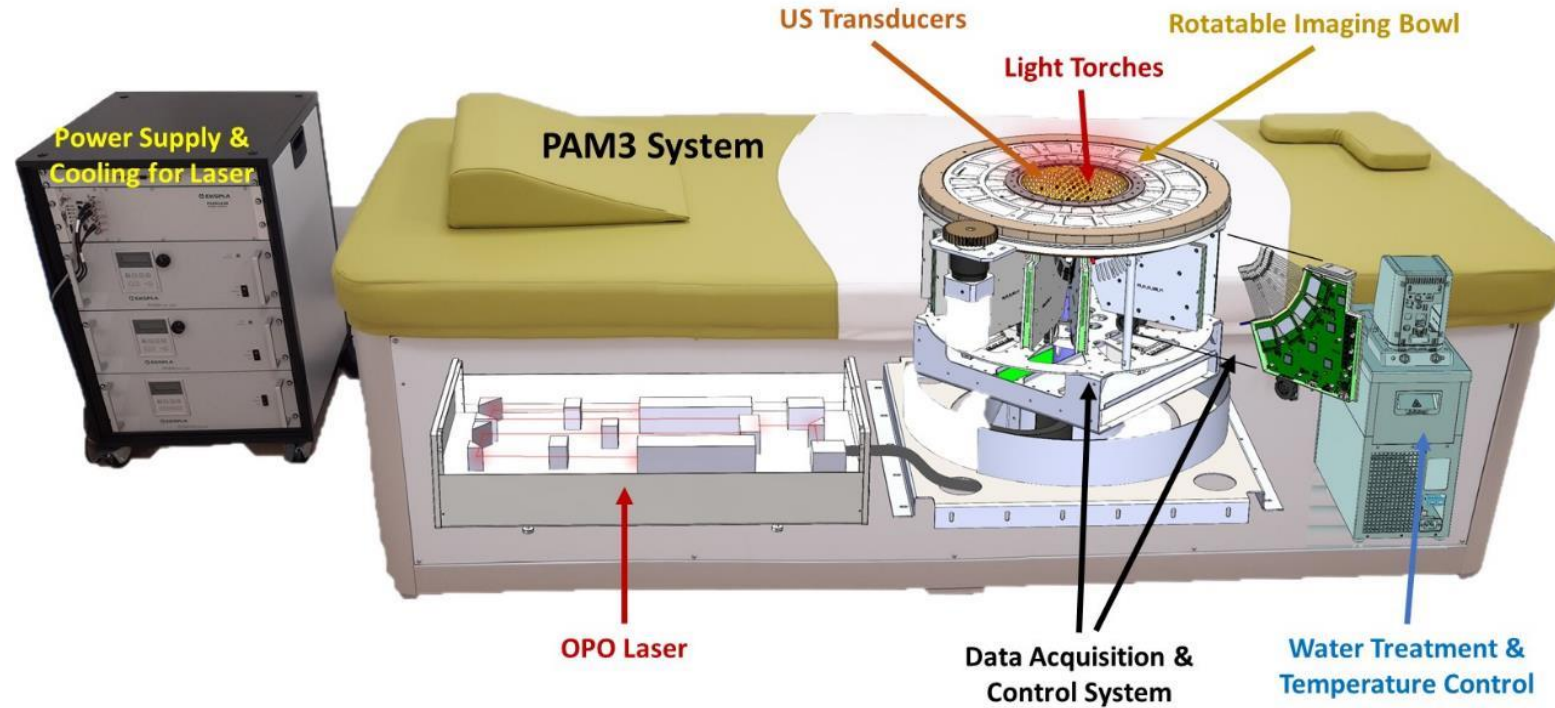


optical fiber bundle (40x)

core of the system – cross section

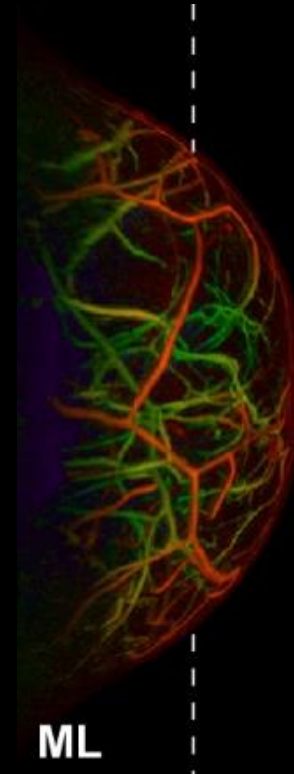
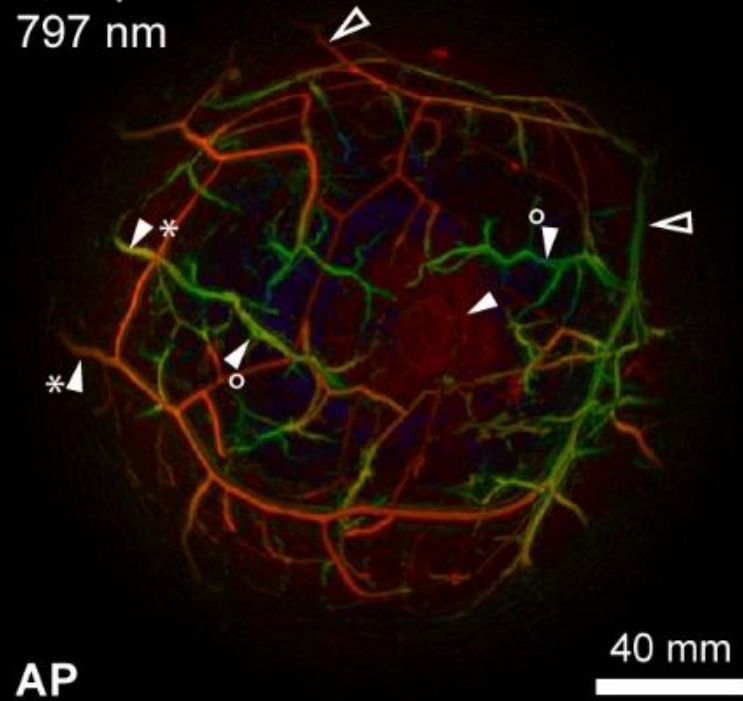


SYSTEM OVERVIEW



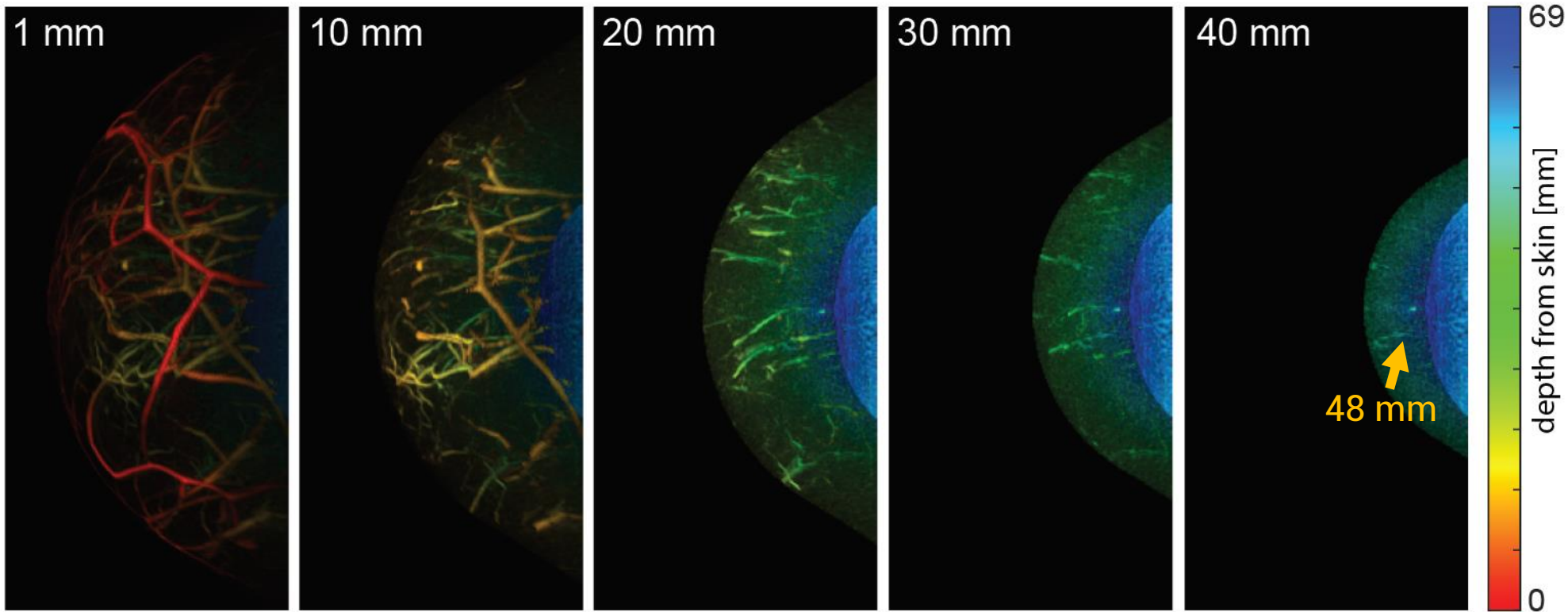
HEALTHY VOLUNTEER – 55 years, brassiere size 90D

L, cup size 8
797 nm



HEALTHY VOLUNTEER 7: IMAGING DEPTH

medial-lateral depth color-coded PAT MIPs



Increasing depth from skin

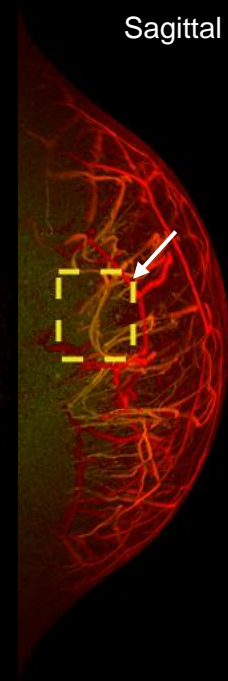
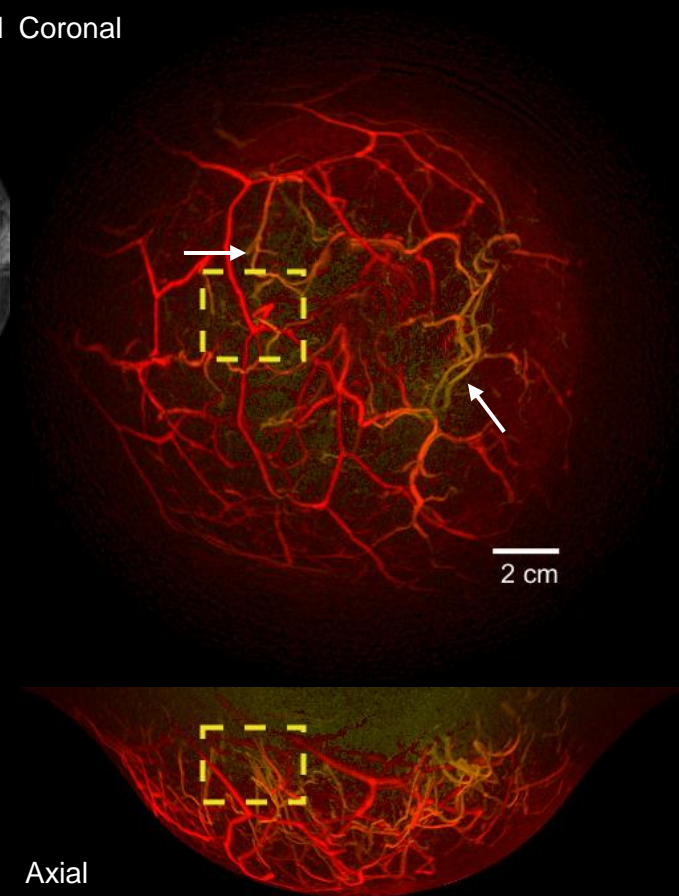
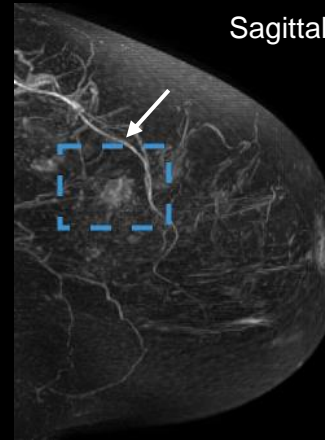
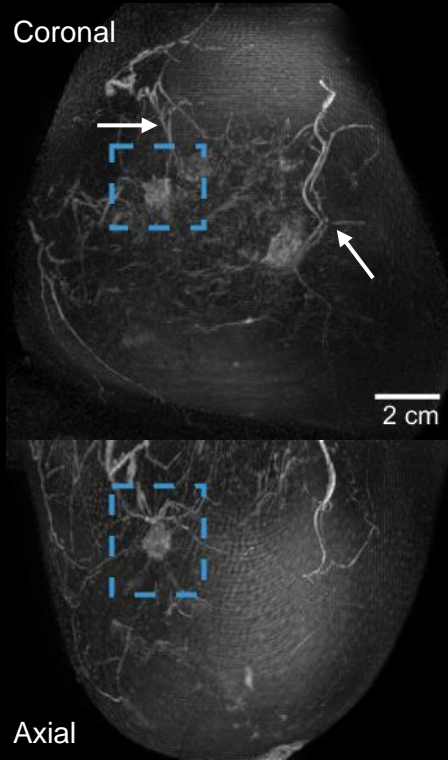
BREAST CANCER PATIENT STUDY **CASE 1**

54 years old

Invasive carcinoma NST grade 1

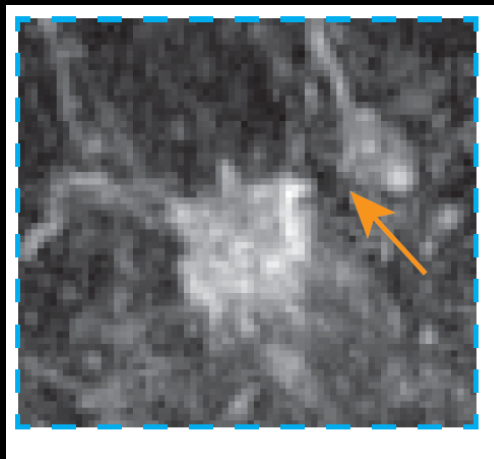
Subtraction MRI MIPs

PAT MIPs

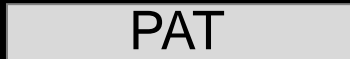

BREAST CANCER PATIENT STUDY **CASE 1**

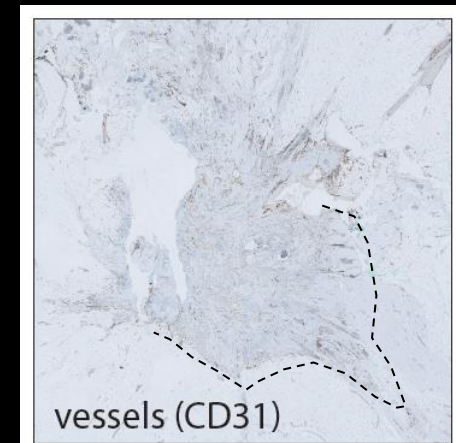
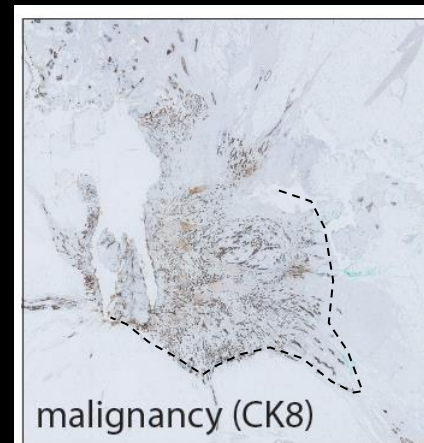
Subtraction MRI



PAT



Histology



BREAST CANCER PATIENT STUDY **CASE 2**

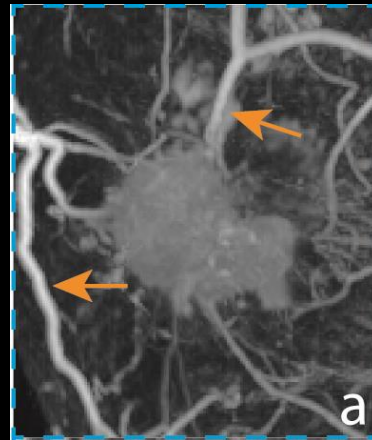67 years old

Invasive carcinoma NST grade 2

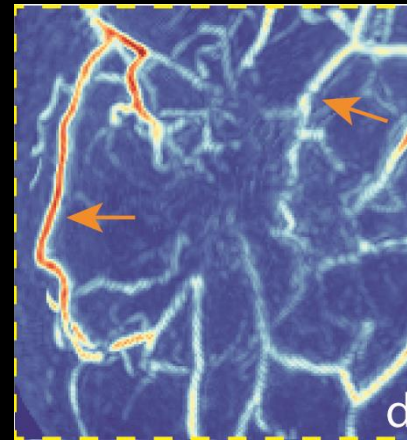
Slice 2 mm

MIP

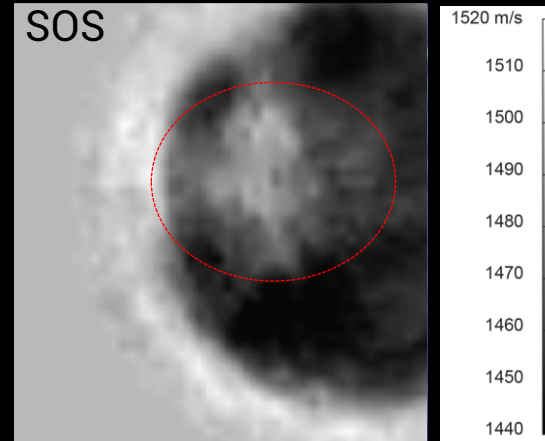
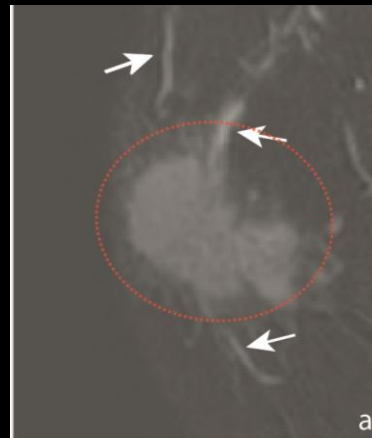
Subtraction MRI



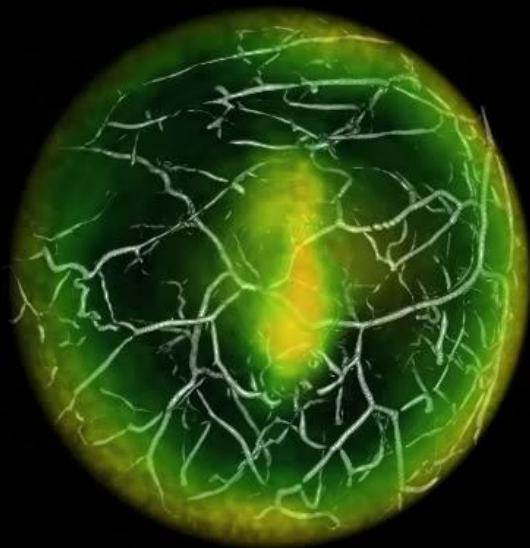
PAT




SOS



overlay

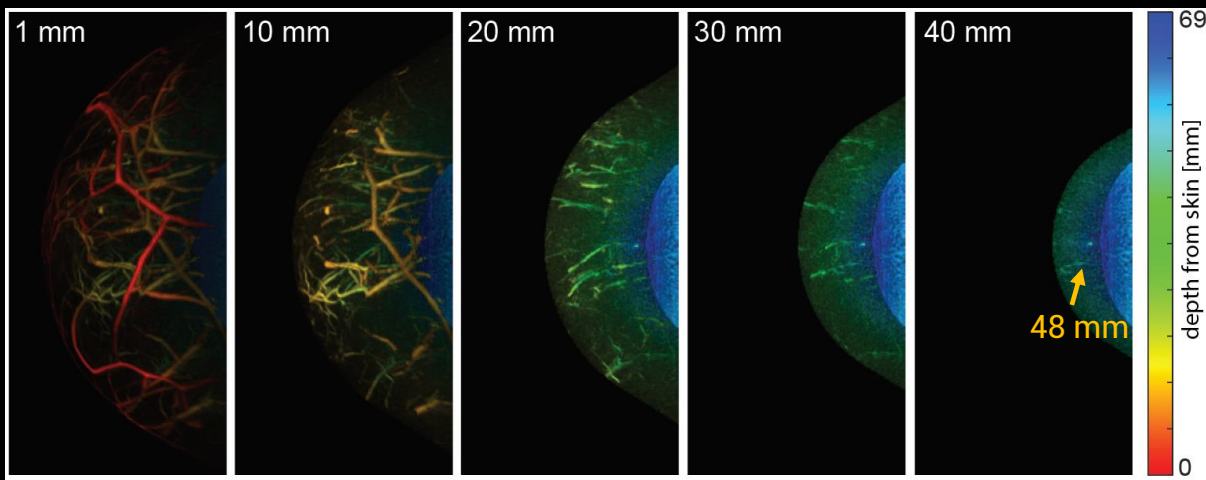
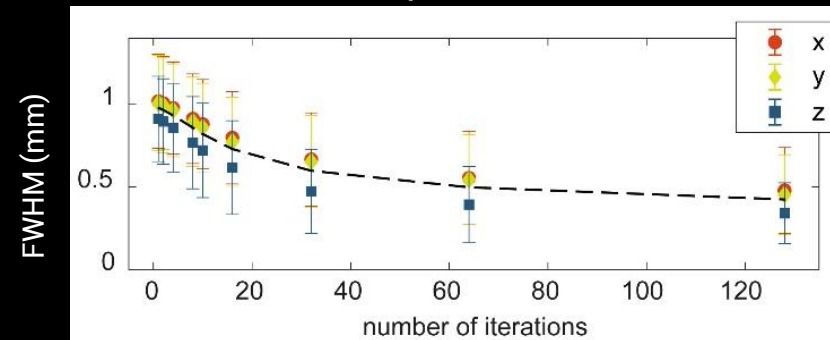


401 positions, 30 averages

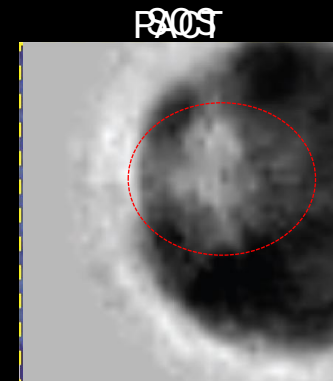
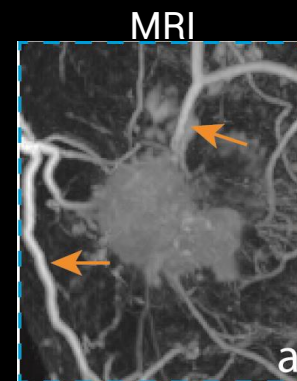


CLOSING THOUGHTS

Isotropic resolution



Patient case



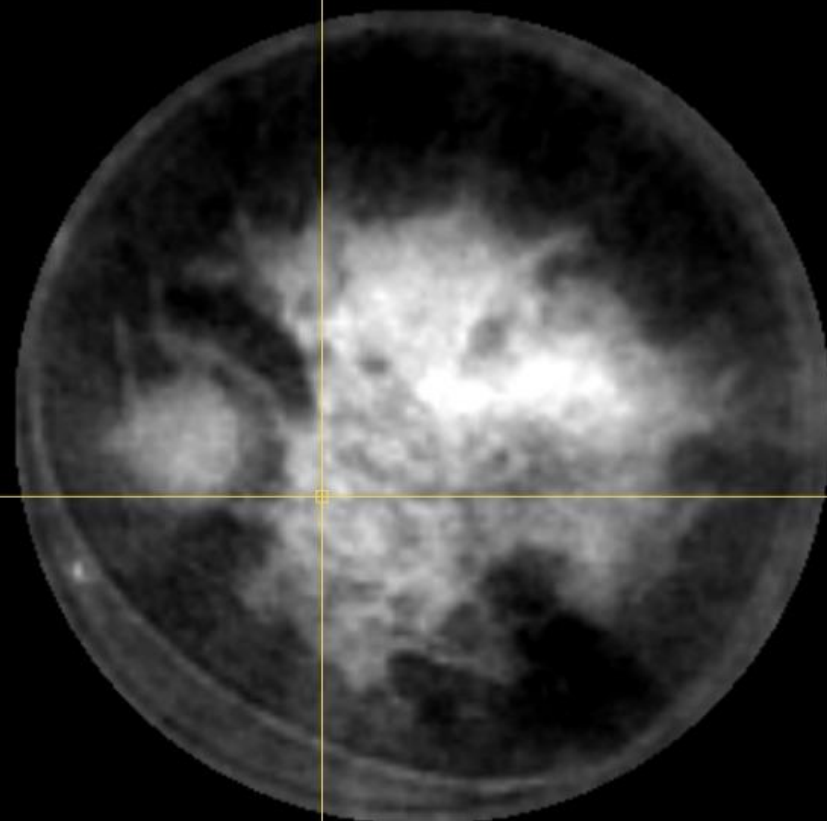
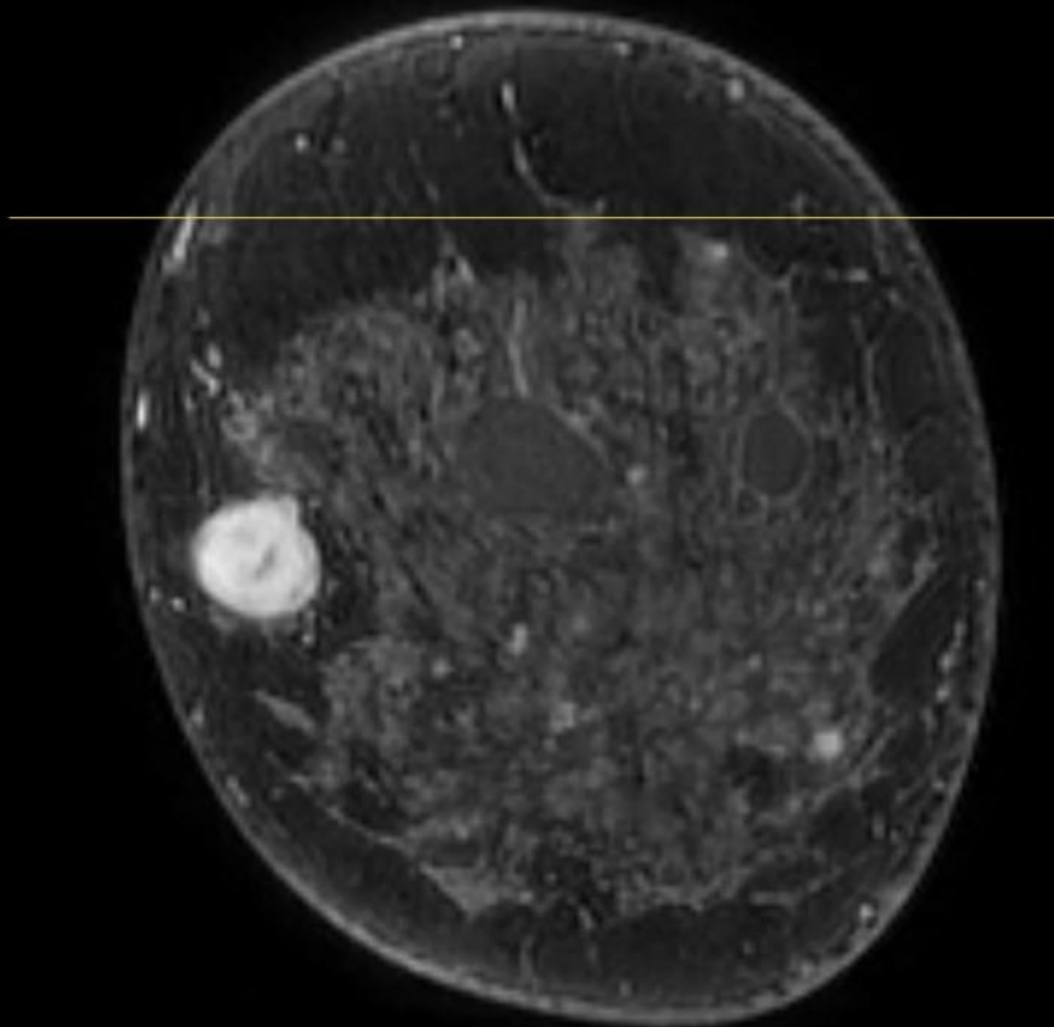
————— Increasing depth from skin —————>

(--): GV

MRI

v

SOS - FWI



10 cm

R